

## ADHESIVE CAPSULITIS (FROZEN SHOULDER)

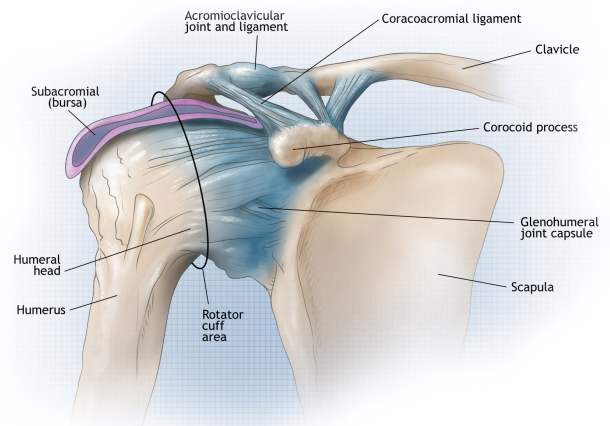
**Frozen shoulder, or adhesive capsulitis** is a condition that generally begins with the gradual onset of pain followed by a limitation of shoulder motion. The discomfort and loss of movement can become so severe that even simple daily activities and even sleep become very difficult. Although much is known about this condition, there continues to be considerable controversy about its causes and the best ways to treat it.

The shoulder is the most mobile joint in the human body, with a complex arrangement of structures working together to provide the movement necessary for daily life. Unfortunately, this great mobility comes at the expense of stability. Several bones and a network of soft tissue structures -- ligaments, tendons, muscles, and the joint capsule -- work together to produce shoulder movement. They interact to keep the joint in place while it moves through extreme ranges of motion. Each of these structures makes an important contribution to shoulder movement and stability. Certain work or sports activities can put great demands upon the shoulder, and injury can occur when the limits of movement are exceeded and/or the individual structures are overloaded.

### What is frozen shoulder?

Frozen shoulder, also called adhesive capsulitis, is a thickening and tightening of the soft tissue capsule that surrounds the glenohumeral joint, the ball and socket joint of the shoulder. When the capsule becomes inflamed, scarring occurs and adhesions are formed. This scar formation greatly intrudes upon the space needed for movement inside the joint. Pain and severely limited motion often occur as the result of the tightening or capsular tissue.

There are two types of frozen shoulder: *primary adhesive capsulitis* and *secondary adhesive capsulitis*.



- **Primary adhesive capsulitis** is a subject of much debate. The specific causes of this condition are not yet known. Possible cause includes changes in the immune system, or biochemical and hormonal imbalances. Diseases such as diabetes mellitus, hypothyroidism, and some cardiovascular and neurological disorders may also be contributing factors. In fact, patients with diabetes have a three times higher risk of developing adhesive capsulitis than the general population. Primary adhesive capsulitis may affect both shoulders (although this may not happen at the same time) and may be resistant to most forms of treatment.

- **Secondary adhesive capsulitis** develops from a known cause, such as stiffness following a shoulder injury, surgery, or a prolonged period of immobilization.

With no treatment, the condition tends to last from one to three years (average of 18 months). Many patients are unwilling to endure the pain and limitations of this problem while waiting for it to run its natural course. Even after many years, some patients will continue to have some stiffness, but no serious pain or functional limitations.

### **What are the signs and symptoms of frozen shoulder?**

The major symptoms of frozen shoulder are **pain** and **loss of motion**.

The onset of symptoms may be gradual or sudden, depending on the cause of the condition. With primary adhesive capsulitis, the onset of symptoms is usually gradual. A sudden onset of symptoms may follow an injury to the shoulder.

The pain and loss of function associated with this condition can become so severe that it can significantly affect the quality of life, and prevent some patients from sleeping well or working.

### **How is frozen shoulder diagnosed?**

The diagnosis of frozen shoulder is made only after a careful history and physical examination is performed. Pain and loss of motion can be symptoms of many shoulder conditions, so a detailed assessment of the shoulder's full range of motion is important. A history of surgery or injury, or the presence of illnesses such as diabetes, is information the physician needs in order to make the correct diagnosis.

It is important to recognize the different patterns of motion loss. Primary adhesive capsulitis is usually associated with loss of motion in all directions. Secondary adhesive capsulitis more often has more defined loss of motion; affecting some movements, but not others.

In most cases, the history and examination are sufficient to determine the presence or absence of frozen shoulder. Advanced imaging such as MRI may occasionally be necessary to confirm the diagnosis and to identify other underlying problems but is usually not necessary.

**X-rays** cannot reveal the cause of shoulder stiffness in most cases of primary adhesive capsulitis. However, in secondary adhesive capsulitis, X-rays can show signs of arthritis, fractures, or metallic plates that may be contributing to motion loss.

An **MRI (Magnetic Resonance Image)** shows soft tissue and may be used in cases in which another disorder is suspected, such as a rotator cuff tear. An MRI is not routinely needed to make the diagnosis of adhesive capsulitis.

An **arthrogram** may be used with an MRI to provide further information about structures in the shoulder. A dye is injected into the shoulder and images are obtained. The dye creates a contrast on the image, making the specific location of adhesions and the reduced space typical of frozen shoulder more visible.

## How is frozen shoulder treated?

### Non-Operative Treatment

For most patients with *primary* adhesive capsulitis, a supervised physical therapy program will restore lost motion, although it usually can take more than six months to accomplish this. It is often necessary to combine a home program with supervised physical therapy for maximum gains. Physical therapy is usually not started early in the process as this may actually worsen symptoms of pain.

Shoulder stiffness that results from *secondary* adhesive capsulitis is generally more resistant to non-operative treatment. A supervised physical therapy program is always tried first. However, **even an aggressive stretching program with an experienced therapist is often ineffective when frozen shoulder follows an injury or previous surgery.**

In many cases, non-steroidal anti-inflammatory medications can be very helpful with this condition. Other treatments such as ice, heat, and ultrasound may help alleviate some of the pain. These treatments are recommended as long as they are effective for the patient. Supervised therapy continues as long as the patient is making improvement. In addition, ultrasound-guided injections of steroid into the shoulder joint are another treatment that can be considered in select cases of adhesive capsulitis. If after 12 to 16 weeks the patient is not improving or is actually getting worse, operative treatment should be considered.

### Operative Treatment

Operative procedures to treat frozen shoulder include **closed manipulation**, as well as **arthroscopic and open capsular release which are surgical procedures**. Operative treatment of primary adhesive capsulitis should only be considered once severe pain has subsided, and discomfort is present only at the extremes of motion. Severe pain represents the inflammatory stage of the disease. **Surgery during this inflammatory phase may actually increase injury to the joint capsule, adding to the patient's loss of motion.**

Most patients who have not done well with a non-operative therapy program will do well with an arthroscopic capsular release procedure that is followed by aggressive motion therapy. It is very important for the first couple of weeks after surgery to be dedicated to a supervised physical therapy program to maintain the motion gains achieved during surgery. Sometimes, a nerve block is maintained following surgery to facilitate physical therapy following surgery.

### Closed Manipulation

**Closed manipulation** is a technique in which the physician stretches and maneuvers the shoulder to break up the scar tissue and adhesions of the joint capsule. Although no incision is made, the patient is usually given a general or regional anesthetic that produces complete relaxation of the muscles. This particular procedure, in isolation, is no longer routinely used as an arthroscopic capsular release allows the surgeon to directly visualize and release the scar tissue and adhesions more precisely.

An arthroscopic capsular release is usually the initial operative approach to primary adhesive capsulitis if physical therapy and injections have not restored adequate motion following an injury or surgery.

If there is a known cause of tightness outside of the joint (which may occur following some shoulder surgeries) an open surgical technique is often necessary. Arthroscopic techniques are not able to effectively access these areas of the shoulder.

Pain management following manipulation is very important. If pain is not controlled, patients tend to limit shoulder motion, allowing scar tissue to form again. To minimize discomfort, long-acting anesthetics are occasionally administered using a nerve block and catheter. A comprehensive stretching program to restore lost motion is then started with a therapist. It is very important that this program begin the day following surgery. Arrangements should be made prior to the procedure. In general, at the beginning, supervised physical therapy should take place 3x/week and be supplemented with a daily home-program. This is especially important for the first 2-3 weeks following surgery in order to maintain motion.

### **Arthroscopic Capsular Release**

Arthroscopic capsular release has been proven to be a safe and effective way to eliminate scar tissue from the capsule. During an arthroscopy, a small fiberoptic instrument is inserted into the joint. The scar tissue surrounding the joint is removed and a gentle manipulation follows. This will significantly reduce the risk of fracture or injury if the frozen shoulder has been present for some time. If necessary, other disorders within the shoulder can be addressed at the same time.

### **Open Release**

On rare occasions, an open procedure to release the adhesions may be required. This may be the case if tightening is present between tissues outside the joint capsule that are not accessible with arthroscopy. Patients who have had previous surgery or a severe joint injury are often candidates for an open release.

### **What types of complications may occur?**

Complications after frozen shoulder surgery are generally infrequent. The most common problems associated with any of these procedures result from too little release, which fails to adequately reduce stiffness, or (very rarely) from too much release, which may cause shoulder instability. Fractures of the humerus have been reported with closed manipulation. Older patients with fragile bones (osteoporosis) are more at risk for this type of complication. In rare cases, previous surgical repairs have been damaged. Although arthroscopic releases are relatively safe, releases in certain areas inside the joint can lead to nerve injury.

### **Non-Operative**

The recovery from non-operative treatment of frozen shoulder can take one to three years (average 18 months). There is a painful phase of the disease followed by a stiffness phase. Patients will first notice the loss of external rotation of the shoulder, followed by elevation of the arm overhead, followed by difficulty reaching behind their back. The pain will then subside gradually, followed by gradual return in motion. Generally, patients regain external rotation first, followed by elevation of the arm overhead. The last part of the arc of motion to return in reaching behind the back (or internal rotation). It is important for patients with frozen shoulder to understand the natural course of the disease and how long it can persist. A home stretching program, combined with a supervised program with a skilled therapist, can speed the recovery process in many cases.

## **Operative**

Following surgery:

Patients are usually discharged home after an overnight stay. During this time, pain medication is delivered through a catheter, which has been placed by our anesthesia colleagues.

By the next day, patients begin an aggressive shoulder motion program supervised by a physical therapist. Again, arrangements should be made *before* the surgery.

Patients are encouraged to use the treated arm for daily activities. A sling is not worn as soon as the nerve block has worn off.

Patients are put on a home stretching program that is to be done between structured therapy appointments. Exercises should be performed 2-3 times per day. Ice (or a cooling unit) are very effective in decreasing pain and inflammation. Pain medications should be used to enhance the ability to stretch the shoulder and perform these exercises.

Surgical incisions are to be kept clean, dry, and covered for the first 7-10 days after surgery.

Progress is closely monitored with regular office visits. Specific weakness or motion limitations are addressed during these visits.

The strengthening phases of a rehabilitation program begins after the patient has achieved a full, pain-free arc of motion. This generally takes at least two months.

## **Why did I develop a frozen shoulder?**

We do not have a good explanation for the development of frozen shoulder in most patients. The majority of cases seem to be more prevalent in women, diabetics, and those with hypothyroidism. Others who develop frozen shoulder are those who have sustained an injury and developed stiffness as a result. The trauma can be quite mild or severe, and the body's response to the event is probably more important than the event itself.

## **How can frozen shoulder be treated?**

The resolution of a frozen shoulder can be very slow, but physical therapy can speed up the healing process. Frozen shoulder begins with pain followed by the rapid development of stiffness. Usually when the pain starts to subside physical therapy can be effective stretching in the capsule back out. Occasionally in unmanageable cases surgery is indicated. This is true only in cases in which the pain has subsided and the residual capsular contracture has not responded to 4-6 months or more of physical therapy. Early surgery in the face of frozen shoulder will lead to more problems with stiffness after surgery.

## **I have been diagnosed with rotator cuff tear in addition to frozen shoulder; why won't the surgeon repair the rotator cuff now?**

Surgery in the face of a frozen shoulder is not recommended because of the immobilization required after rotator cuff repair. The shoulder becomes more inflamed after the surgery and the immobilization required to heal the cuff repair leads to increased stiffness. The only way to deal with the combination of problems is to allow physical therapy to stretch out the frozen shoulder. Once that has been accomplished, the rotator cuff repair can be performed. The shoulder will probably be stiffer than the average cuff repair after the immobilization period ends, but research has shown that physical therapy can help regain lost motion.

For more information, please refer to Dr. Costouros' website: [www.stanfordshoulder.com](http://www.stanfordshoulder.com)